



# Concurrent *Staphylococcus aureus* Septicaemia and Septic Arthritis in Dengue Infection

Deng Enfeksiyonunda Eş Zamanlı *Staphylococcus aureus* Septisemi ve Septik Artrit

K. Jagadish Kumar<sup>1</sup>([iD](#)), M. Meghana<sup>1</sup>, Harshitha Jagwani<sup>1</sup>, Harish Reddy<sup>1</sup>

<sup>1</sup> Department of Pediatrics, JSS Academy of Higher Education and Research, Mysore, India

**Cite this article as:** Kumar KJ, Meghana M, Jagwani H, Reddy H. Concurrent *Staphylococcus aureus* septicaemia and septic arthritis in Dengue infection. J Pediatr Inf 2019;13(4):e172-e175.

## Abstract

In tropical countries coinfections with dengue fever have been increasingly reported in various combinations. Usually fever lasts for 5-7 days in dengue illness. The possibility of co-infection is considered when fever persists beyond the anticipated period. Dengue fever usually manifests with significant severe arthralgia and myalgia, however dengue virus is not considered an arthritogenic virus. We report a child of dengue infection who presented with persisting fever with left lower limb pain diagnosed as concurrent staphylococcal septicaemia with septic arthritis.

**Keywords:** Dengue fever, prolonged fever, staphylococcal septicaemia, septic arthritis

## Öz

Tropikal ülkelerde, Deng humması ile birlikte görülen enfeksiyon sayısı ve kombinasyon çeşitliliği son yıllarda artmış oranlarda bildirilmektedir. Deng hastalığında ateş genellikle 5-7 gün arasında sürmektedir. Ateş, öngörülen süreden daha uzun sürdüğünde bir koenfeksiyon ihtimali göz önünde tutulur. Deng virüsü artritogenik bir virüs olarak kabul edilmese de Deng humması kendini sıklıkla şiddetli artralji ve miyalji ile göstermektedir. Bu çalışmada biz, süregelen ateş ve alt ekstremitte ağrısı ile başvuran ve stafilokok septisemi ve septic artrit tanısı alan bir çocuğu bildirdik.

**Anahtar Kelimeler:** Deng humması, uzamış ateş, stafilokok septisemi, septic artrit

## Introduction

The clinical spectrum of dengue is highly variable, ranging from a mild flu-like syndrome to severe disease, with shock and haemorrhage (1). In tropical countries coinfections with dengue fever have been reported in various combinations (2,3). Bacteraemia with dengue co-infection is rare (4). Therefore timely diagnosis of coinfections is a challenge, if not coinfections may lead to life-threatening consequences. Dengue fever usually manifests with significant severe arthralgia and myalgia, however dengue virus is not considered an arthritogenic virus (5). We report a child of dengue infection who

presented with persisting fever with left lower limb pain diagnosed as concurrent staphylococcal septicaemia with septic arthritis and osteomyelitis.

## Case Report

Previously health 9 year old boy presented with fever for 3 days and puffiness of face for 3 days. On examination he was febrile (temp 38.8°C), PR 96/min, RR 24/min, BP 90/60 mmHg, capillary filling time (CFT) < 3 seconds and oxygen saturation 99% at room air. He had flushing of the body with erythematous macular rashes more on the lower limbs, puffiness of face and bilateral conjunctival suffusion. Investigations and the course of the illness are depicted in the Table 1 and Figure 1.

## Correspondence Address / Yazışma Adresi

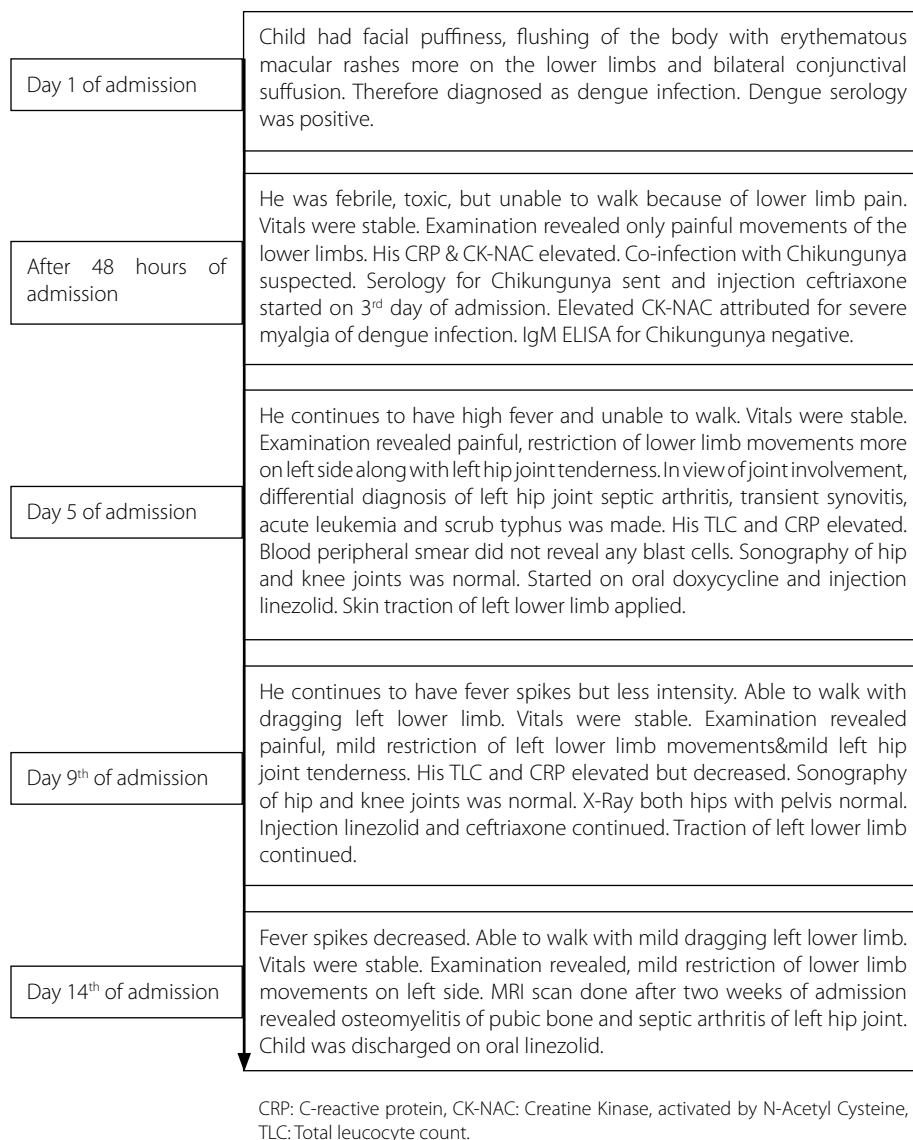
K. Jagadish Kumar

Department of Pediatrics,  
JSS Academy of Higher Education and Research,  
Mysore, India

E-mail: jagdishmandya@gmail.com

Received: 26.02.2018

Accepted: 04.12.2018



**Figure 1.** Sequence of events after admission.

## Discussion

Co-infections with malaria, leptospirosis, typhoid fever, chikungunya virus as well as other organisms have been reported with dengue illness (1,2,6). Bacterial co-infections in dengue fever have been increasingly reported (7). According to the review by Trunfio et al. 0.18%-7% of dengue infections are accompanied by concurrent bacteremia (8). Out of 9553 dengue cases, bacteremia was detected 29 (0.3%) of patients and the commonest bacteria being *Staphylococcus aureus* (48.3%). Concurrent bacteremia (positive bacterial blood culture within 72 hours of admission) was diagnosed in 62.1% cases and *S. aureus* was the commonest organism (7). Araújo et al. reported 14 year old boy initially diagnosed with

classical dengue fever, who subsequently developed a fatal septic shock caused by *S. aureus* (1). Among 5000 cases with symptomatic dengue infection in Taiwan, seven cases had bacteremia (9). Lee et al. observed bacteremia in 5.5% of the patients among 774 patients presenting with DHF [Dengue Haemorrhagic Fever]/DSS [Dengue shock syndrome] (9). Out of 114 dengue fever, two grew *S. aureus* in a study from Delhi (10). A study from Singapore observed cluster of *S. aureus* and dengue -co-infection and all of them had skin and soft tissue infection (4). Our dengue illness child had concurrent *S. aureus* bactremia and presented as lower limb pain due to septic arthritis and osteomyelitis. In view of joint involvement, differential diagnosis of left hip joint septic arthritis, transient

**Table 1.** Investigations

Investigations	Admission	3 <sup>rd</sup> day	4 <sup>th</sup> day	5 <sup>th</sup> day	6 <sup>th</sup> day	7 <sup>th</sup> day	9 <sup>th</sup> day	11 <sup>th</sup> day
Hemoglobin (g/dL)	10.9	9.6	9	8.8	8		8.7	8.4
PCV (%)	31.9	29.2	26.2	25.4	23		27	26
TLC (cells/mm <sup>3</sup> )				15.900		16.200	13.090	16.370
N, L, E, B, M (%)				53, 40, 3, 3, 1		48, 47, 1, 3, 1	46, 47, 1, 5, 1	68, 26, 1, 4, 1
CRP (mg/L)		115.7		152		85.5	49.4	42.7
Platelet count (lakhs/mm <sup>3</sup> )	1.23	1.37	1.41	1.65	1.57	1.3	1.27	2.16
ESR mm 1 <sup>st</sup> hr						95	10	
SGOT (U/L) SGPT (U/L)	45 110							
CK-NAC (N= 0-109 U/L)		200					56	
Sonography abdomen			Gall bladder wall edema and wall thickness of 6 mm	Gall bladder wall edema and wall thickness of 6 mm, ascites				
Sonography hip and knee joints				Normal		Normal	Normal	
X-Ray both hips with pelvis						Normal		
Kidney functions and chest X-Ray normal. Serology for Dengue: -Mac Capture ELISA for IgM positive, ELISA NS 1 Antigen positive, Peripheral smear for malarial parasite, weil -felix and widal test negative IgM ELISA for Chikungunya negative. Blood culture grew <i>Staphylococcus aureus</i> sensitive to oxacillin, linezolid, vancomycin, clindamycin, daptomycin, erythromycin and resistant to penicillin-G, ciprofloxacin. MRI scan done after two weeks of admission revealed osteomyelitis of pubic bone and septic arthritis of left hip joint. PCV: Packed cell volume, TLC: Total leucocyte count, N: Neutrophil, L: Lymphocyte, B: Basophils, ESR: Erythrocyte sedimentation rate, CRP: C-reactive protein, CK-NAC: Creatine kinase, activated by N-Acetyl Cysteine, SGOT: Serum glutamic-oxaloacetic transaminase, SGPT: Serum glutamic pyruvic transaminase.								

synovitis, acute leukemia and scrub typhus was made. Dengue infection is associated with severe arthralgia and myalgia (5). Dengue virus is not considered an arthritogenic virus. But Chikungunya virus can cause arthritis (5,6). Therefore co-infection with Chikungunya was suspected in view of elevated C-reactive protein (CRP), but serology for Chikungunya was negative. Scrub typhus can present with myalgias, however his weil-felix test was negative. His peripheral blood smear did not show any blast cells. Our child continues to have fever for more than 7 days, had elevated leucocyte count and CRP with left hip joint tenderness. Therefore septic arthritis was kept as diagnosis and injection linezolid was started inspite of normal sonography of the joints. However MRI [Magnetic Resonance Imaging] scan done after two weeks of admission revealed osteomyelitis of pubic bone and septic arthritis of left hip joint.

Thein et al. observed that patients with dengue and concurrent bacteremia are more likely to be critically ill, have DSS, higher neutrophil count, lower lymphocyte count, hemo-

concentration with thrombocytopenia at admission (7). Lee et al. concluded that patients with prolonged fever, higher frequencies of acute renal failure, gastrointestinal bleeding, altered consciousness, unusual dengue manifestations and DSS should be assessed for possible co-infection (9). However our child was not critically ill, never had bleeding tendencies/severe thrombocytopenia or kidney injury. Co-infection has been shown to worsen the outcome of dengue infection (9). Bacteremia seems to accounts for 14.3% to 44.4% of dengue-related deaths among various studies (7). Hypotheses on the pathogenesis of concurrent bacteremia in patients with dengue include disintegration of endothelial cells by antibodies against dengue non structural protein and/or relative immunosuppression. The disintegration of endothelial cells may allow the entry of bacteria into the bloodstream leading on to bacteremia (1,7). In Dengue, fever is the initial symptom which would camouflage any septicaemia (10). The possibility of co-infection was considered when fever persisted beyond the anticipated period characteristic of dengue fever. In dengue

illness, usually fever lasts for 5-7 days. Lee et al. opined that patients with DHF/DSS who also have prolonged fever (> 5 days) are at high risk for concurrent bacteremia. In our child fever spikes continued for more than 10 days. As the mortality is very high in bacteremia associated with dengue-infection collection of blood cultures and empiric antibiotic therapy may be considered in patients who are critically ill (7).

### Conclusion

While treating dengue cases, careful attention should be given to the natural clinical course and high index of suspicion is necessary to identify concurrent bacteremia so that the morbidity and mortality can be decreased.

**Informed Consent:** Informed consent taken.

**Peer-review:** Externally peer-reviewed.

**Author Contributions:** Concept - KJK, MM, HJ; Design - KJK, MM, HJ; Supervision - KJK; Data Collection and/or Processing - HJ, HR; Analysis and/or Interpretation - HJ, HR; Literature Review - HJ, HR; Writing - KJK, HR; Critical Review - KJK.

**Conflict of Interest:** The authors have not reported a conflict of interest.

**Financial Disclosure:** There is no financial support in this study.

### References

1. Araujo SA, Moreira DR, Veloso JMR, Silva JO, Barros VL, Nobre V. Fatal staphylococcal infection following classic dengue fever. *Am J Trop Med Hyg* 2010;83:679-82. [\[CrossRef\]](#)
2. Pancharoen C, Thisyakorn U. Coinfections in dengue patients. *Pediatr Infect Dis J* 1998;17:81-2. [\[CrossRef\]](#)
3. Kumar KJ, Chavan A, Anitha C, et al. Concurrent dengue infection and *Pseudomonas aeruginosa* septicemia with classical ecthyma gangrenosum in an infant. *J Pediatr Infect Dis* 2014;9:197. [\[CrossRef\]](#)
4. Chai LY, Lim PL, Lee CC, Hsu LY, Teoh YL, Lye DC, et al. Cluster of *Staphylococcus aureus* and dengue co-infection in Singapore. *Ann Acad Med Singapore* 2007;36:847-50.
5. Jayamali WD, Herath HMMTB, Kulatunga A. A young female presenting with unilateral sacroiliitis following dengue virus infection: a case report. *J Med Case Report* 2017;11:307. [\[CrossRef\]](#)
6. Kumar KJ, Manjunath VG, Shailashree M, Girish GN. Coinfection of dengue and chikungunya in a child-a case report. *J Indian Med Assoc* 2012;110:749-52.
7. Thein TL, Ng EL, Yeang MS, Leo YS, Lye DC. Risk factors for concurrent bacteremia in adult patients with dengue. *J Microbiol Immunol Infect* 2017;50:314-20. [\[CrossRef\]](#)
8. Trunfio M, Savoldi A, Viganò O, d'Arminio Monforte A. Bacterial coinfections in dengue virus disease: what we know and what is still obscure about an emerging concern. *Infection* 2017;45:1-10. [\[CrossRef\]](#)
9. Lee IK, Liu JW, Yang KD. Clinical characteristics and risk factors for concurrent bacteremia in adults with dengue hemorrhagic fever. *Am J Trop Med Hyg* 2005;72:221-6. [\[CrossRef\]](#)
10. Arya SC, Agarwal N. Concurrent dengue fever and bacterial septicemia during the 2008 dengue outbreak in Delhi. *Dengue Bulletin* 2008;32:226-7.