

The Discoloration of Finger Nail Due to Doxycycline

Arzu Karlı¹, Sema Gülnar Şensoy¹, Sevinç Nursev Özsevik², Nurşen Belet¹

¹Division of Pediatric Infection Diseases, Ondokuz Mayıs University Faculty of Medicine, Samsun, Turkey

²Division of Pediatrics, Ondokuz Mayıs University Faculty of Medicine, Samsun, Turkey

Abstract

Tetracycline accumulating in bone and tooth densed with mineralization can cause dental discoloration and disorder of skeleton development. Although skin and dental discoloration is the most common adverse effect of doxycycline, nail discoloration is rarely seen. In the present case, a 17-year old girl with discoloration of her finger nails was reported during doxycycline treatment for brucellosis.

(*J Pediatr Inf* 2014; 8: 187-9)

Key words: Nail discoloration, doxycycline

Introduction

Doxycyclines are semi-synthetic, lipophilic-structured and tetracycline-derived broad spectrum antibiotics. Due to their long half-life periods, low resistance potential, safe side effect profiles and affordable prices, they are, in clinical practice mainly for brucellosis infections, used for the treatment of various infections. Tetracyclines accumulate in by creating a chelate together with calcium ions (especially in tooth, cartilage and bones). This causes development disorders in teeth and bones and discoloration (1). It has been known since 1950s when these groups of drug-use started for the first time that they cause permanent yellow color change and tooth enamel hypoplasia (1, 2). Hyperpigmentation on the skin again is common in many tetracycline derivatives. These phototoxic reactions are rarely seen in the use of doxycyclines (3). Doxycycline-related the discoloration of finger nail is rarely reported in the literature (4, 5). In our article, we presented the case of a patient who received doxycycline treatment due to brucellosisinfection and who was monitored to have brown color change in her finger nail.

Case Report

A 17-year-old girl was admitted with week-long night time complaints of high fever and shivering; she was later referred to our hospital based upon the detection of pancytopenia in her tests. The family involved in stockbreeding had the history of consuming cheese made out of raw milk. The patient did not have any peculiarity in her background or family history. In the physical examination, body temperature was: 39 °C, pulse: 126/min, blood pressure: 120/80 mm/Hg. Body weight was: 50 kg (10-25 percentiles), boy: 162 cm (25-50 percentiles), in abdomen examination, liver and spleen midclavicular and even 3-4 cm soft-edged could be handled. In laboratory examinations, the following values were obtained; hemoglobin 9.5 gr/dL, leucocyte count 2520/mm³, thrombocytocount 90,000/ mm³, erythrocyte sedimentation rate 24 mm/hour, C-reactive protein (CRP) 123 mg/L, aspartateaminotransferase (AST) 219 U/L, alanineaminotransferase (ALT) 95 U/L, viral examinations were normal Rose Bengal test of the patients were positive and standard brucellosis agglutination testwas 1/320. The patient who had *Brusella melitensis* isolated in her blood culture

Received: 03.06.2013
Accepted: 27.07.2013
Available Online Date:
31.09.2013

Correspondence

Address:
Arzu Karlı,
Ondokuz Mayıs
Üniversitesi Tıp Fakültesi,
Çocuk Enfeksiyon
Hastalıkları Bilim Dalı,
Samsun, Türkiye
Phone: +90 530 870 71 18
E-mail:
drarzukarli@yahoo.com
©Copyright 2014 by Pediatric
Infectious Diseases Society -
Available online at
www.jpediatrinf.org
doi:10.5152/ced.2013.48



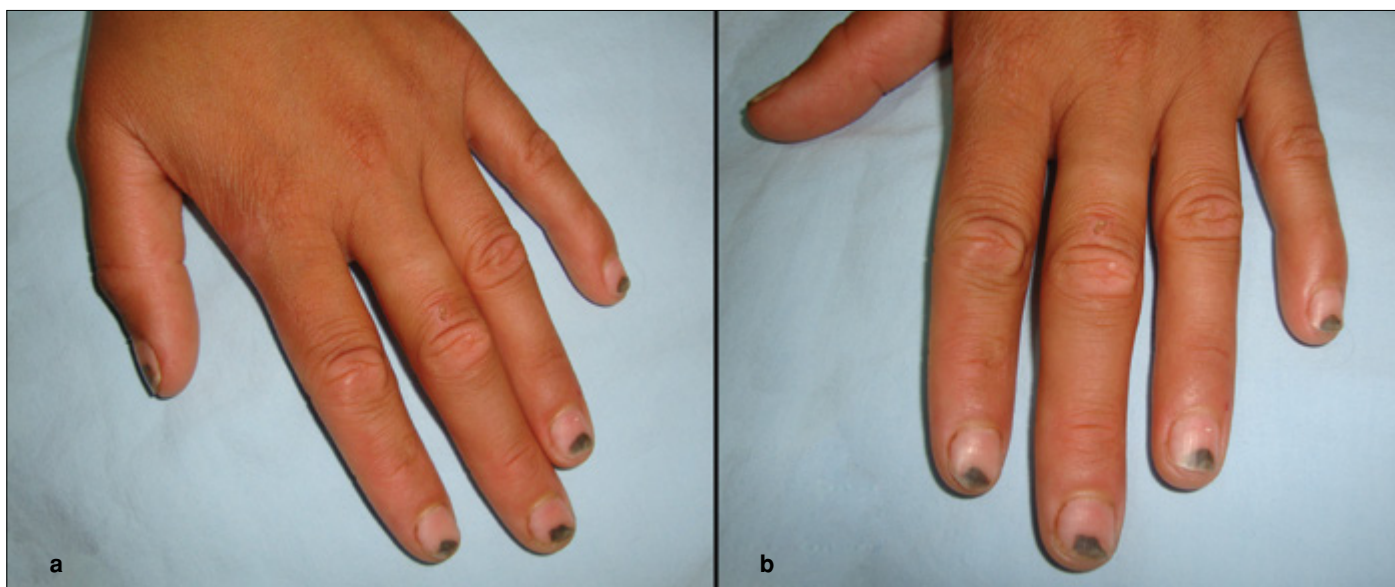


Figure 1a, b. Discoloration on the finger nails

was orally given doxycycline 4 mg/kg/day (2x100 mg) and rifampicin 20 mg/kg/day (1x600 mg) in maximum dose for the treatment of brucellosis. The patient's fever dropped on the third day of the treatment and her hepatosplenomegaly receded on the third day; also the following values were observed: hemoglobin was 10.7 gr/dL and white blood cell count 3,600/mm³; thrombosis count rose to 278,000/mm³ e and AST was: 29 U/L, ALT: 32 U/L, CRP: 9 mg/L; eventually, the patient was discharged from the hospital for the treatment to be completed in six weeks. When the patient came back for control on the fortieth day, brown color change was observed on her fingers nail that had been going on for twenty days (Figure 1a, b). Following the discontinuation of doxycycline and rifampicin treatment, it was observed that the discoloration on the finger nails of the patient started to get better in the next control one month later.

Discussion

Tetracyclines are broad spectrum antibiotics effective against many gram negative and gram positive bacteria, intracellularly-localized *Brucellosis*, *Chlamydia*, *Mycoplasmas* and *Rickettsias*. They are especially used prevalently in the treatment of brucellosis (6). Tetracycline group antibiotics constitute tetracycline calcium complex against the calcified tissues by attaching to calcium due to their affinity and cause discoloration on the skin, tooth, a little bit on the finger nails as well (7). The discoloration on the skin and finger nails is a phototoxic reaction. Although free oxygen radicals emerging through effect of ultraviolet rays are thought of selectively causing mitochondrial damage in the cell, its mecha-

nism is unable to be clearly explicated (8). The lack of antioxidant capacity of the individual paves the way for the development of this condition. It was revealed that in patients with low antioxidant capacity such as cystic fibrosis and lack of vitamin, photosensitive increased (4, 9).

Direct exposure of the finger nails to the sun's rays, lack of melanin pigment in the nail fold protecting it against the ultraviolet rays, the fact that the fingers act as a convex lens increasing the penetration of ultraviolet rays under the finger and their potential to be able to be exposed to more trauma may help to explicate why phototoxic damage occurs on the finger nails more intensively (4).

There are also studies suggesting that dose-related phototoxicity has increased. In study, it was revealed that when doxycycline was taken as 200 mg/day, it generated more phototoxic reaction in comparison to when it was taken as 150 mg/day (10). Phototoxic effect is more common in summer months when ultraviolet ray exposure is greater. Therefore, it is important for patients to be protected from sun rays during the treatment period. Our patient started to be treated in summer and failed to protect herself from the sun's rays.

Conclusion

In conclusion, it should be remembered that discoloration on the finger nails as a rare side effect may occur as result of doxycycline use and following the discontinuation of the treatment, this condition may spontaneously get better. Patients should be recommended to protect themselves from sun's rays while taking doxycycline.

Peer-review: Externally peer-reviewed.

Informed Consent: Written informed consent was obtained from patients who participated in this study.

Author Contributions: Concept - A.K., G.S.; Design - A.K., S.Ö.; Supervision - G.S.; Funding - A.K., S.Ö.; Materials - A.K., S.Ö.; Data Collection and/or Processing - A.K., S.Ö.; Analysis and/or Interpretation - A.K., G.S.; Literature Review - A.K., G.S.; Writing - A.K., G.S.; Critical Review - G.S., N.B.; Other - S.Ö., N.B.

Conflict of Interest: No conflict of interest was declared by the authors.

References

1. Shetty AK. Tetracyclines in pediatrics revisited. *Clin Pediatr* 2002; 41: 203-9. [\[CrossRef\]](#)
2. Ayaslioglu E, Erkek E, Oba A, et al. Doxycycline- induced staining of permanent adult dentition. *Aust Dent J* 2005; 50: 273-5. [\[CrossRef\]](#)
3. Cunha BA. Doxycycline re-revisited. *Arch Intern Med* 1999; 159: 1006-7. [\[CrossRef\]](#)
4. Yong CK, Prendiville J, Peacock DL, et al. An unusual presentation of doxycycline- induced photosensitivity. *Pediatrics* 2000; 106: E13. [\[CrossRef\]](#)
5. Akcam M, Artan R, Akcam FZ, et al. Nail discoloration induced by doxycycline. *Pediatr Infect Dis J* 2005; 24: 845-6. [\[CrossRef\]](#)
6. Roberts MC. Tetracycline therapy: update. *CID* 2003; 36: 462-7 [\[CrossRef\]](#).
7. Van der Bijl, Pitigoi- Aron G. Tetracyclines and calcified tissues. *Ann Dent* 1995; 54: 69-72.
8. Shea CR, Olack GA, Morrison H, et al. Phototoxicity of lumi-doxycycline. *J Invest Dermatol* 1993; 101: 329-33. [\[CrossRef\]](#)
9. Dominguez C, Gartner S, Linan S, et al. Enhanced oxidative damage in cystic fibrosis patients. *Biofactors* 1998; 8: 149-53. [\[CrossRef\]](#)
10. Layton AM, Cunliffe WJ. Phototoxic eruptions due to doxycycline- a dose related phenomenon. *Clin Exp Dermatol* 1993; 18: 425-7. [\[CrossRef\]](#)