

## ***Painful Rash Localized on the Left Thigh: What is Your Diagnosis?***

Cihangül Bayhan<sup>1</sup>, Zeynel Abidin Öztürk<sup>2</sup>, Damla Hanoğlu<sup>2</sup>, Ateş Kara<sup>1</sup>

<sup>1</sup>Department of Pediatrics, Division of Pediatric Infection Diseases, Hacettepe University Faculty of Medicine, Ankara, Turkey

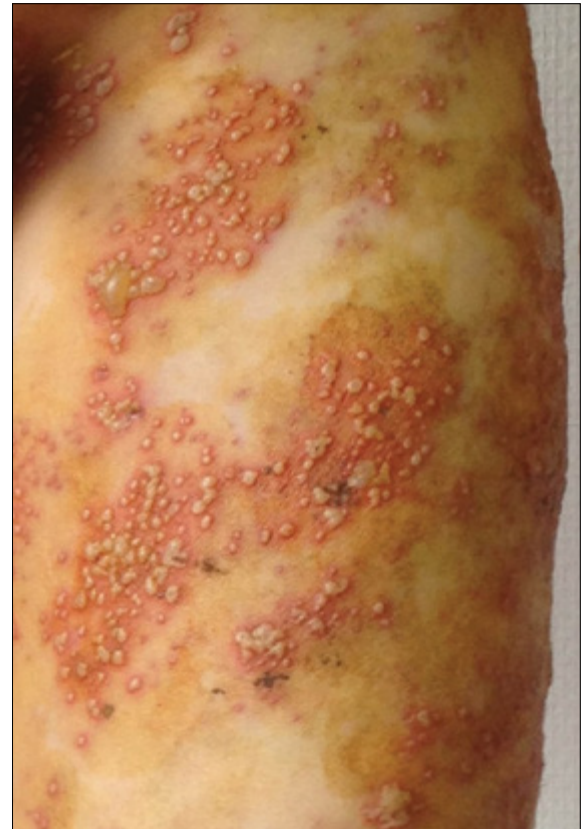<sup>2</sup>Department of Pediatrics, Hacettepe University Faculty of Medicine, Ankara, Turkey

### **What is your diagnosis?**

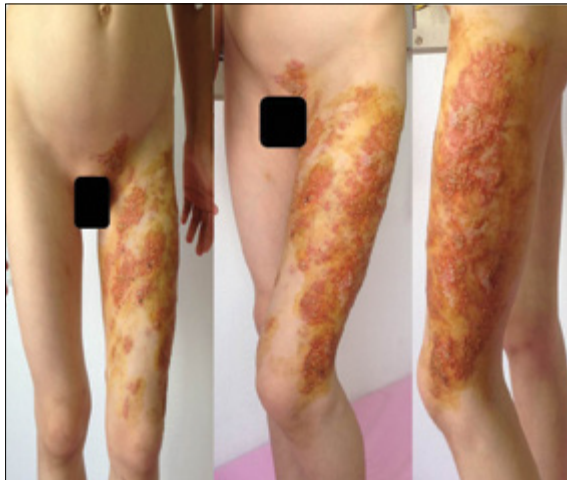
An eight-year old male patient applied with the complaints of a rash that started on the left patella five days earlier and gradually spread. We were informed that while there was no itching initially, itching started on the second day and rashes started to spread over front part of the thigh and left inguinal region; upon these symptoms, the family applied wet soil (mud) and then topical mupirocin and polyvinylpyrrolidone recommended by a private health institution; and there was no accompanying fever and no one in the immediate family who had similar rashes. There was no specificity in the personal and family history of the patient. In the physical examination, there were knee-level vesicular and bullous rashes in the left inguinal region and front side of the left thigh (Figure 1, 2). Other

system examinations were normal. In the laboratory examinations, hemoglobin in the total blood count was 12.9 g/dL, white blood cell count 5,900/mm<sup>3</sup>, platelet count 146,000, erythrocyte sedimentation rate 4 mm/hour, C-reactive protein 0.46 mg/dL, and liver and kidney function tests were normal.

What is your diagnosis of this patient?



**Figure 2.** Up-close view of the rash, vesicular in the same phase



**Figure 1.** Extensive vesicular rashes localized on the thigh

Received: 17.02.2015  
Accepted: 06.05.2015

#### **Correspondence**

#### **Address:**

Cihangül Bayhan  
E-mail:  
cihangulbayhan@gmail.  
com

©Copyright 2015 by  
Pediatric Infectious Diseases  
Society - Available online at  
www.cocukenfeksiyon.org  
www.jpdiatrinf.org

DOI:10.5152/ced.2015.1752



*Note: The discussion of this case is underway in the 140 page.*

## What is your diagnosis? (Continued)

### Instructive Case (Continued)

## Left thigh localized painful rash: What is your diagnosis?

### Discussion

Since the lesions did not exceed the midline and they had a distribution typical of 1st, 2nd and 3rd lumbar dermatome regions and were in the same phase with vesicular character, zona zoster diagnosis was made. It was learnt that the patient had varicella when 40 days old. When the history of the patient was investigated in more detail, it was learnt that the parent of the patient had to deal with the hospitalized grandfather with lung cancer diagnosed 20 day earlier, and the patient had to stay at home with his twin and during this period, the parents of the patient expected him to take on more responsibility from the patient. It was thought that the emotional stress experienced by the patient might have triggered the illness. The patient was hospitalized with the diagnosis of common varicella zoster and intravenous acyclovir and sulbactam-ampicilline treatment was started. Since it was learnt that the mud was applied over the lesions and the patient was given no tetanus vaccine in the last 5 years, the tetanus vaccine was shot. Since the patient had the common zona, he was investigated for immune deficiency and no significant finding was found in the history; it was found that the quantitative immunoglobulin levels and lymphocyte sub-groups were normal. The antiviral treatment of the patient was discontinued after the 5th day and the patient was discharged with the condition that the antibiotic treatment would continue orally. In the first control a week after the discharge from the hospital, it was seen that the recovery was on course without any problem.

Varicellazostervirus (VZV) is a virus of Alphaherpesvirinae family with its only natural source being the humans. As it ends up with varicella with its primary infection, VZV causes latent infections in the sensory ganglions and also leads to clinical tables termed as varicella zoster or zona with its reactivation (1).

The risk of contracting varicella zoster in their life times in individuals who have had varicella is between 1-20%, and 75% of the cases have the condition after the age of 45. While the frequency of the disease in the general population is 3,4/1.000 person-year, its frequency in children under 10 years is less going down to as slow as 0,2-0,74/1.000 person-year. However, the frequency of varicella zoster in the early adolescent period is greater in those who have had varicella in early childhood (2). The greatest risk factor for zona in seemingly healthy children is the primary varicella infection experienced in the intra-

uterine period or in the first year of a person's life; the incidence in this case rises to 4,1/1.000 person-year. When a person suffers from the varicella at very early age, the antibodies acquired from the mother through placenta protects the infant; however, this hinders the sufficient cellular and humoral response. The brief period for the zona to develop in these patients makes us think that the developing VZV-specific immune response is less (3).

Zona is characterized with vesicular lesions concentrated in a limited way to a single sensory dermatome. Initially, it generates a separate varicella-like vesicular subsequently leading to growth and merging in the rashes. Localized pain developing simultaneously with the rashes or before the rashes, hyperesthesia and itching may occur. Formation of new lesions in primary dermatome finishes in 3 to 7 days in healthy persons, but itching may continue as long as two weeks (4). Postherpetic neuralgia table commonly seen in adults and putting the patient in a difficult situation is not expected in healthy children. The varicella zoster frequency in children who have previously had varicella and have a suppressed immune system is greater; a more serious clinical table may be seen in those cases (5). Varicella zoster infection in children with suppressed immune system may cause serious local dermatomal and systemic infections. The presence of lesions in the regions away from the primary dermatome or in the neighboring dermatomes is indicative of VZV viremia and these patients have greater risks in terms of systemic spread. Through the haematogenous spread of the reactive VZV, pneumonia, hepatitis, encephalitis and common intravascular coagulopathy may be seen. With the patients who had stem cell transplantation leading the way, seemingly-atypical, non-localized varicella zoster lesions may develop in patients with high degree suppressed immune systems, and the appearance of the commonly-spread vesicular lesions may not easily be distinguished from varicella (6).

Since vesicular or vesicular and papular rash may occur in the differential diagnosis of the varicella zoster infections, varicella, molluscum contagiosum, herpes simplex virus infections and enterovirus infections may be considered. As the lesions were composed of vesicles and bullae that were inclined to merge, had dermatomal distribution and do not exceed the midline, our patient was initially thought to have varicella zoster.

Acyclovir is the most frequently used agent in the treatment of varicella and varicella zoster infections. Similar to famciclovir and valacyclovir, nucleoside analogues look structurally like acyclovirs, and are more efficiently absorbed intestinally after the oral intake. These drugs were licensed for the treatment of varicella zoster in adults, but the experiments in this field in children is limited (7). As the acyclovir is eliminated by the kidneys, it is essential

that the patient is enabled to take in fluids and dose adjustment be made in patients with renal failure (8).

The varicella vaccine was added to the national vaccine calendar in our country in 2013. As a result, the number of pediatric zona cases is expected to decline, but the possibility of vaccine-related zona development should also be kept in mind.

## References

1. Lungu O, Annunziato PW, Gershon A, et al. Reactivated and latent varicella-zoster virus in human dorsal root ganglia. *Proc Natl Acad Sci USA* 1995; 92: 10980-4. [\[CrossRef\]](#)
2. LaRussa PS, Marin M. Varicella-Zoster Virus Infections. In: Kliegman RM, Stanton BF, Geme JWS, Schor NF, Behrman RE (eds). *Nelson Textbook of Pediatrics*. 19th edition. Philadelphia: W.B. Saunders Company; 2011. p. 1104-10. [\[CrossRef\]](#)
3. Rodriguez-Fanjul X, Noguera A, Vicente A, Gonzalez-Ensenat M.A, Jimenez R, Fortuny, C. Herpes zoster in healthy infants and toddlers after perinatal exposure to varicella-zoster virus: a case series and review of the literature. *Pediatr Infect Dis J* 2010; 29: 574-6. [\[CrossRef\]](#)
4. Whitley RJ. Varicella - Zoster Virus. In: Mandell GL, Bennett JE, Dolin R (eds.). *Mandell, Douglas and Bennett's Principles and Practice of Infectious Diseases*, 7th edition. Philadelphia: Churchill Livingstone; 2010. p.1963-9. [\[CrossRef\]](#)
5. Kanra G, Kara A. Varisella zoster virüs enfeksiyonları. *Çocuk Sağlığı ve Hastalıkları Dergisi* 2002; 45: 260-74
6. Arvin AM. Varicella-Zoster Virus. In: Long SS, Pickering LK, Prober CG (eds.). *Principles and Practice of Pediatric Infectious Diseases*, 4th edition. Philadelphia: W.B. Saunders Company; 2012. p. 1035-44.
7. Kara A. Varisella Zoster Virüs Enfeksiyonlarında Asiklovir Kullanımı. *J Pediatr Inf* 2007; 1: 162-6
8. Heininger U, Seward JF. Varicella. *Lancet* 2006; 368: 1365-76. [\[CrossRef\]](#)